

Intradiscal Injection of Autologous Platelet-Rich-Plasma for the Treatment of Lumbar Disc Degeneration -Preliminary Prospective Clinical Trial for Discogenic Low Back Pain Patients-

+¹Akeda, K; ¹Imanishi, T; ³Ohishi, K; ⁴Masuda, K; ¹Uchida, A; ²Sakakibara, T; ²Kasai, Y; ¹Sudo, A

Department of ¹Orthopaedic Surgery and ²Spinal Surgery and Medical Engineering, Mie University Graduate School of Medicine, Mie, Japan, ³Transfusion Service, Mie University Hospital, Mie, Japan, ⁴Department of Orthopaedic Surgery, University of California, San Diego
k_akeda@clin.medic.mie-u.ac.jp

INTRODUCTION:

Intervertebral disc (IVD) degeneration is an important clinical problem that often contributes to low back pain and degenerative disc diseases. Degeneration of the IVD induces annulus tears and fissures, which can cause severe discogenic low back pain. Because the IVD has little potential to self-regenerate, treatment of degenerative disc disease is one of the most challenging clinical problems facing the spine surgeon.

Platelet-rich plasma (PRP) is a fraction of plasma that contains platelets and multiple growth factors concentrated at high level. Because activated platelets have the potential to release growth factors including IGF-1, TGF- β , PDGF and EGF, PRP has been clinically used to accelerate wound healing and tissue regeneration in orthopedic and oral surgery [1]. The soluble releasate isolated from platelet-rich-plasma (PRP) has recently been demonstrated to influence the metabolism of intervertebral discs *in vitro* [2]. Furthermore, an intradiscal injection of autologous PRP has been shown to induce restoration of structural changes in the rabbit annular injection model *in vivo* [3].

Based on a preclinical study, we performed a preliminary clinical trial to determine the safety and efficacy of an intradiscal injection of autologous PRP-releasate in patients with discogenic low back pain. Furthermore, for safety in clinical use, we have isolated autologous PRP-releasate by activating PRP using autologous serum instead of bovine thrombin.

METHODS:

Patients: Inclusion criteria for this study included chronic low back pain without leg pain for more than 3 months; one or more lumbar discs (L3/L4 to L5/S1) with evidence of degenerative changes on magnetic resonance imaging (MRI) (Figure 1A); and at least one symptomatic disc confirmed using standardized provocative discography (Figure 1B). The soluble releasate, isolated from clotted PRP, was injected (2.0 ml) into the center of the nucleus pulposus under fluoroscopic guidance (Figure 1C). Outcome measures included the visual analog scale (VAS), Roland-Morris Disability Questionnaire (RDQ), X-ray and MRI (T2-quantification: before treatment and 4 months after treatment).

Platelet-rich plasma preparation: The isolation of PRP and its releasate was performed at blood transfusion center of our institution under typical good manufacturing practices (GMP) guideline. Whole blood (200 ml) with an anti-coagulant was first centrifuged at 3,000xg for 10 minutes at room temperature to form a buffy coat layer containing platelets and leukocytes. The red blood cells were collected and stored for autologous transfusion at surgery. The buffy coat layer was resuspended in 20 ml of plasma and then centrifuged at 150xg for 15 minutes to separate the platelets from leukocytes and residual red cells. The resulting supernatant (PRP) was then transferred to a storage bag. Autologous serum was prepared from the 10 ml of coagulated whole blood by centrifuging for 10 minutes at 3000xg.

Preparation of PRP-releasate: A mixture of autologous serum and 2% CaCl₂ was added to PPP for clot (gel) formation. After incubation for 30 minutes at room temperature, the supernatant was isolated from the PRP gel by centrifugation (3000xg, 5 minutes). The samples were kept at -20°C until used.

MRI Analysis: MRI examinations were performed using a 3.0-Tesla (Achieva 3.0T, PHILIPS, Amsterdam, The Netherlands). T2-weighted images in the axial plane were obtained using standard clinical multi-echo spin T2 mapping sequence. For T2-quantification, the mean signal intensities were determined in the regions of interest (ROI) framing the outer border of AF.

Statistical Analysis: Differences of VAS and RDQ score, MRI T2-values were assessed for statistical significance by the paired T-test.

RESULTS:

Data were analyzed from 6 patients (3 men, 3 women; mean age 34.4 years-old) who had completed 6 months follow-up. The mean platelet count of PRP was about 4.7 times greater than that of whole blood

(Whole blood: 277.8 x 103/ μ l, PRP: 1371.1 x 103/ μ l). After treatment, no patient showed adverse events or significant narrowing of disc height. The mean pain score before treatment was significantly decreased at one month (VAS score: 7.1 \pm 1.2 to 1.8 \pm 2.0, p<0.01; RDQ score: 11 \pm 1.8 to 3.2 \pm 2.4, p<0.01); this was sustained for six months after treatment (Figure 2A). The mean T2 values did not change significantly four months after treatment (p=0.18) (Figure 2B).

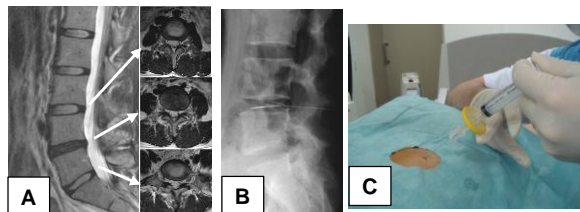


Fig. 1: Case Presentation (Fig. 2A-C)

A 24-year-old woman presented with severe low back pain persisting for several years. MRI (T2) of the lumbar spine showed decreased intensity on the L4-L5 disc (Fig. 1A). The symptomatic disc was confirmed using standardized provocative discography on the L4-L5 disc (Fig. 1B). Autologous PRP-releasate was injected (2.0 ml) into the center of the nucleus pulposus under fluoroscopic guidance (Fig. 1C).

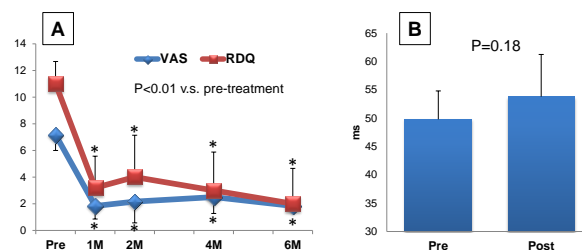


Fig. 2: Change in VAS and RDQ score (A) and mean T2-value (B)

DISCUSSION:

For the first time, we have performed a preliminary clinical study of a biological therapy for degenerative disc diseases using autologous PRP. We have successfully isolated autologous PRP-releasate from activated PRP using autologous serum instead of a clinical dose of bovine thrombin.

The results of this study showed that the intradiscal injection of autologous PRP-releasate in patients with low back pain has been shown to be safe and effective for six months after treatment. Future long-term follow-up and/or randomized control studies should be performed to evaluate the effects of this therapy.

SIGNIFICANCE:

We have performed a preliminary clinical study of biological therapy for lumbar disc degeneration. The intradiscal injection of autologous PRP-releasate in patients with low back pain has been shown to be safe and effective in reducing back pain for six months after treatment.

ACKNOWLEDGEMENTS:

This study was sponsored by grants from the Ministry of Education, Culture, Sports, Science and Technology (Japan).

REFERENCES:

[1] Carter CA, Exp Mol Pathol 74: 244, 2003. [2] Akeda, K+, Spine 31 (9):125, 2006. [3] Obata, S. et al., ORS transactions 36, 0674, 2011.